




# Journal of the Nigerian Infectious Diseases Society



Case Report

## The Scourge of Typhoid in Sub-Saharan Africa: A Rare Case of Symmetrical Lower Limb Gangrene with Colonic Perforation

Daniyan M<sup>1</sup>, Nduka VS<sup>1\*</sup>, Yau D<sup>1</sup>, Abdulwahab A<sup>1</sup>, Saudat B<sup>1</sup>, Gana A<sup>1</sup>, Abdulkadir A<sup>1</sup>, Ibrahim F<sup>1</sup>, Ndagi A<sup>1</sup>, Yusufu LMD<sup>1</sup>

1. Surgery Department Ahmadu Bello University Teaching Hospital, Zaria Kaduna State Nigeria

\*Corresponding author:

[vitussunday6061@gmail.com](mailto:vitussunday6061@gmail.com)

Received: 21 May 2025

Revised: 3 Jul 2025

Accepted: 15 Aug 2025

Published: 24 Oct 2025

DOI

10.58539/JNIDS.2025

### ABSTRACT

**Background:** Typhoid fever remains a major public health concern in sub-Saharan Africa, with its complications contributing significantly to morbidity and mortality. While gastrointestinal perforation is a recognized complication, the development of symmetrical peripheral gangrene (SPG) is exceedingly rare and poorly understood. We present a unique and severe case of typhoid fever complicated by both colonic perforation and symmetrical lower limb gangrene in a young adult male.

**Case Presentation:** A 25-year-old male with no significant comorbidities presented with a 7-day history of high-grade fever, abdominal pain, and prostration. His background included risk factors such as consumption of untreated water and frequent patronage of roadside food vendors. Clinical evaluation, laboratory results (including high titres of *Salmonella typhi* O and H antigens, leucopenia with relative lymphocytosis), and intraoperative findings supported a diagnosis of typhoid septicaemia. Emergency laparotomy revealed multiple perforations in the caecum and ascending colon with unremarkable ileum. Postoperatively, the patient developed progressive dry gangrene of both feet, despite preserved popliteal pulsations and absence of disseminated intravascular coagulopathy (DIC). Management included resuscitation, broad-spectrum antibiotics, vitamin C, and eventual bilateral forefoot amputations. Antiphospholipid antibody testing and thrombolytic therapy were not conducted due to resource limitations.

**Discussion:** This case underscores the protean manifestations of typhoid fever and highlights the possible mechanisms of SPG, including endotoxin-mediated endothelial injury, microvascular thrombosis, and low-flow states. Early recognition and aggressive management of systemic sepsis are critical, but adjunctive therapies such as anticoagulation, thrombolysis, and antioxidant use may offer additional benefit in halting gangrene progression.

**Conclusion:** Colonic perforation with symmetrical peripheral gangrene represents a rare but life- and limb-threatening complication of typhoid fever. Clinicians in endemic regions must maintain a high index of suspicion and advocate for early multidisciplinary intervention to improve outcomes in such complex presentations.

**Keywords:** typhoid sepsis, lower limb gangrene, intestinal perforation

## INTRODUCTION

Typhoid fever (enteric fever) is a systemic, potentially fatal infection caused predominantly by *Salmonella enterica* serovar Typhi, and to a lesser extent by serovars Paratyphi A, B, and C.<sup>1,2</sup> Transmission occurs via the fecal–oral route, and high attack rates are observed in regions with inadequate sanitation and overcrowding. Although widespread vaccination campaigns, improved water quality, and antimicrobial stewardship have reduced its incidence in many settings, typhoid fever remains a major public health challenge across sub-Saharan Africa.

The incidence of typhoid fever in sub-Saharan Africa is estimated at 100–310 cases per 100 000 population per year, with age-adjusted mortality rates up to 1.5 per 100 000.<sup>3,4</sup> Disparities in healthcare infrastructure, limited access to effective antibiotics, and emerging multidrug resistance contribute to the continued high burden of disease in this region. Clinically, enteric fever spans a spectrum from mild gastroenteritis-like illness to fulminant sepsis. A life-threatening sequela is typhoid intestinal perforation (TIP), most frequently occurring in the terminal ileum, with reported rates ranging from 0.8% to 39%, markedly higher in low- and middle-income countries than in high-income settings.<sup>5</sup> Cecal perforation is rare, accounting for only 0.1%–1.8% of all TIP cases.<sup>6</sup> Despite advances in surgical techniques and perioperative care, mortality from TIP in resource-poor environments remains high, ranging from 5% to 80%, due to delays in presentation, diagnostic challenges, and limited critical-care support.<sup>5</sup>

Beyond gastrointestinal complications, typhoid fever may give rise to diverse extraintestinal manifestations, including myocarditis, neuropsychiatric disturbances, and osteomyelitis.<sup>7</sup> Symmetrical peripheral gangrene is an exceedingly rare but catastrophic complication, with only a handful of cases reported worldwide.<sup>8</sup> Proposed mechanisms include endotoxin-mediated microvascular thrombosis, disseminated intravascular coagulation, and septic vasculitis, yet the pathophysiology remains incompletely defined.

Herein, we present a rare case of symmetrical bilateral lower limb gangrene in association with typhoid-induced colonic perforation in a young adult male. This report underscores the need for heightened clinical vigilance for atypical presentations of enteric fever and contributes to the limited literature on its severe vascular complications.

## CASE PRESENTATION

A 25-year-old male undergraduate presented to our tertiary facility with a 4-day history of fecal discharge from an abdominal wound and progressive bilateral lower limb discoloration. His symptoms began approximately two weeks prior with high-grade intermittent fever and headache, for which he self-medicated with over-the-counter antimalarial drugs obtained from a patent medicine vendor, without clinical improvement.

Approximately seven days into the illness, the patient developed lower abdominal pain, initially dull in character but later became generalized. This was accompanied by abdominal distension, multiple episodes of vomiting, and worsening weakness. He sought care at a peripheral hospital where he underwent an emergency exploratory laparotomy. Operative details were unavailable. Three days postoperatively, he developed fecal leakage from the surgical wound, persistent abdominal pain, and constipation.

Simultaneously, he experienced a burning sensation in both feet, followed by darkening of the toes. The discoloration progressed rapidly to involve both lower limbs up to the mid-calf level. He denied any history suggestive of peripheral vascular disease, intermittent claudication, diabetes mellitus, or sickle cell disease. His source of drinking water was untreated tap water, and he regularly consumed meals from roadside food vendors.

He was subsequently referred to our center for expert surgical and multidisciplinary management. On arrival, the cardiothoracic surgery team recommended a computed tomography (CT) angiogram to evaluate for large-vessel occlusion. The orthopedic team advised conservative monitoring for demarcation of the gangrenous limbs prior to determining the level of amputation.

Clinical examination revealed an acutely ill-looking, febrile (temperature: 38.2°C), pale, mildly icteric, and dehydrated young man. He was hemodynamically compromised with a pulse rate of 112 beats per minute and blood pressure of 90/64 mmHg. Cardiovascular examination was unremarkable, with normal first and second heart sounds and no murmurs. Respiratory rate was 26 cycles per minute with oxygen saturation of 98% on room air. Chest examination revealed symmetrical expansion with good air entry bilaterally and no adventitious sounds.

Abdominal examination showed distension with partial dehiscence of the lower midline laparotomy wound, through which fecal matter was discharging. There was diffuse abdominal tenderness and clinical features of localized peritonitis. Digital rectal examination revealed an empty rectum and boggy of the rectovesical pouch.

Examination of the lower limbs revealed bilateral discoloration involving the distal half of both legs. The limbs were edematous, with multiple bullous eruptions, tender to palpation, and exhibited differential warmth. Peripheral pulses were absent in both the dorsalis pedis and posterior tibial arteries, while the popliteal pulses remained palpable bilaterally.

Initial laboratory investigations showed hemoglobin of 13.2 g/dL, leukopenia with a white blood cell count of  $2.5 \times 10^9/L$  (neutrophils 45%, lymphocytes 68%), and thrombocytosis (platelet count of  $416 \times 10^9/L$ ). Coagulation profile was within normal limits (INR 1.1). Widal test titers were 1:160 to H antigen and 1:360 to O antigen. Screening for retroviral infection, hepatitis B surface antigen, and hepatitis C virus was negative. Serum electrolytes, urea, and creatinine were largely within normal range, with a potassium level of 4.1 mmol/L and urea of 7 mmol/L. Serum protein and albumin were also within normal limits.

An urgent abdominopelvic ultrasound scan revealed pelvic fluid collections suggestive of intraperitoneal sepsis. The patient was taken for an emergency exploratory laparotomy.

Exploratory laparotomy revealed approximately 750 mL of feculent peritoneal fluid. There was extensive caecal perforation (Figure 4), as well as two separate perforations on the ascending colon: one measuring  $4 \times 4$  cm in the proximal third and another measuring  $3 \times 3$  cm in the mid portion, both located along the anti-mesenteric border. Surrounding these sites were areas of necrotic retroperitoneal soft tissue. The small bowel was grossly normal.

A right limited hemicolectomy was performed with exteriorization of both the transverse colon and terminal ileum. Necrotic retroperitoneal tissues were debrided. The patient was commenced on intravenous fluid resuscitation, intravenous meropenem (1 g every 8 hours), intravenous clindamycin (300 mg every 8 hours), and adequate analgesia. Oral intake was initiated 48 hours postoperatively, and oral vitamin C (500 mg tds) was introduced upon commencement of oral sips.

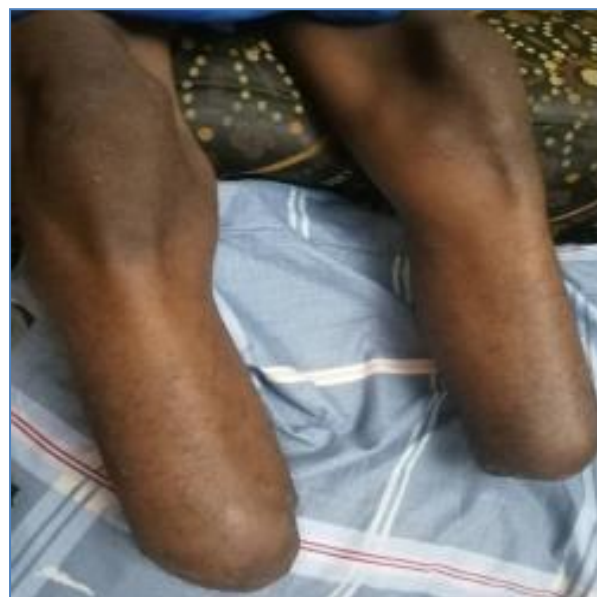A Doppler ultrasound and computed tomography (CT) angiography of the abdominal aorta and lower limb vessels were performed on postoperative day four. These imaging studies revealed patent major vessels with no evidence of arterial occlusion.

By postoperative day seven, proximal regression of bilateral lower limb edema and gangrenous changes was noted. However, peripheral pulses—posterior tibial and dorsalis pedis—remained faintly palpable. A diagnosis of postoperative enterocutaneous fistula (ECF) with bilateral lower limb wet gangrene secondary to typhoid septicemia was established.

Repeat laboratory investigations showed a packed cell volume (PCV) of 29%, serum potassium of 3.1 mmol/L, and urea of 11 mmol/L, with normal serum creatinine. Urinalysis revealed concentrated, low-volume urine output. Blood cultures were negative, and Widal test was not repeated. The patient was resuscitated with intravenous fluids, potassium chloride supplementation, two units of packed red blood cells, and escalation of antibiotic therapy to meropenem 2 g stat, followed by 1 g every 8 hours, in addition to intravenous clindamycin and omeprazole.

Following clear demarcation of necrotic tissue, the orthopedic team proceeded with bilateral below-knee amputation (Figure 1). The patient subsequently underwent successful stoma reversal and is currently stable and doing well under follow-up.

**Figure 1: amputated limbs**



## DISCUSSION

Typhoid fever, primarily caused by *Salmonella enterica* serovar Typhi and Paratyphi, remains endemic in sub-Saharan Africa due to poor sanitation, limited access to clean water, and persistent food hygiene challenges. Transmission is classically via the "4Fs": flies, fingers, faeces, and fomites. The severity of clinical manifestations is influenced by bacterial virulence, host immunity, and prior antimicrobial exposure, with increasing resistance to first-line antibiotics such as fluoroquinolones and cephalosporins contributing to treatment failures.<sup>1</sup>

Our index case—a 25-year-old male—does not fit the classical high-risk demographics (children and elderly) but presents with multiple established risk factors, including male gender, use of unsafe water sources, and consumption of food from roadside vendors, as previously documented in endemic settings.<sup>2</sup>

Typhoid pathogenesis follows five well-characterized phases: incubation, bacteraemia, lysis, septicaemia, and convalescence.<sup>7</sup> The pathogen's ability to bypass the innate immune defenses via Vi-capsule and survive intracellularly within macrophages using type III secretion system (TTSS) contributes to systemic dissemination.<sup>7</sup> Our patient's symptoms—step-ladder fever, prostration, and abdominal pain—occurred during the septicemic phase and mimic malaria, contributing to a diagnostic delay, a common occurrence in endemic areas.<sup>3</sup>

While the terminal ileum is the most frequent site of intestinal perforation in typhoid fever due to its abundant Peyer's patches,<sup>7</sup> intraoperative findings in this patient revealed extensive caecal and ascending colon perforations. Such presentations, though rare, have been reported and attributed to high bacterial loads, delayed presentation, or variation in gut immunity and vascularity.<sup>4</sup> The diagnosis was supported by clinical history, a high Widal titre (H: 1:160; O: 1:360), and leucopenia with relative lymphocytosis—typical haematologic findings in typhoid septicaemia.<sup>8</sup>

The patient presented with severe sepsis and enterocutaneous fistula (ECF), requiring urgent resuscitation, surgical intervention, and broad-spectrum empirical antibiotics—meropenem and clindamycin. Similar management strategies have been advocated in resource-limited settings where blood cultures are frequently negative due to prior antimicrobial use.<sup>3,9</sup> Blood cultures were sterile in our patient, likely due to pre-hospital antibiotics, a factor known to reduce diagnostic yield to as low as 60% in the first week of illness.<sup>8</sup>

Although cultures of bone marrow and duodenal aspirates offer higher sensitivity, they are rarely done in our setting due to cost and technical challenges.

Symmetrical peripheral gangrene (SPG) is an exceptionally rare but life-threatening complication of typhoid fever. The exact pathophysiology remains incompletely understood but is thought to involve endotoxin-mediated vascular injury, microthrombi formation, and the Schwartzman reaction.<sup>8</sup> These lead to occlusion of small vessels despite palpable large vessel pulses, a pattern consistent with our patient's findings (intact popliteal but absent dorsalis pedis and posterior tibial pulsations).

There was no clinical or laboratory evidence of disseminated intravascular coagulation (DIC), a key differential consideration. The role of antiphospholipid antibodies—reported by Yoo et al. in SPG related to *Klebsiella* sepsis—could not be assessed in our patient due to limited access to serological assays.<sup>8</sup>

The use of antioxidants, notably high-dose Vitamin C, has been proposed to mitigate the endothelial damage induced by reactive oxygen species in SPG.<sup>8</sup> Our patient commenced oral Vitamin C (500 mg TDS) postoperatively, with partial regression of oedema and improved demarcation, but ultimately required bilateral below-knee amputations due to established gangrene.

Thrombolytic and anticoagulant therapy with fresh frozen plasma (FFP) and heparin has been used in other reports to arrest progression, especially in patients with intact distal pulses.<sup>8</sup> These interventions were not deployed in our case due to late presentation and unavailability.

This case shares features with previously reported cases, such as that by Anyanwu et al., of typhoid with ECF and peripheral gangrene in an unstable patient requiring aggressive resuscitation and surgery.<sup>3</sup> However, multiple colonic perforations with SPG make our case notably rare. Most literature describes either ileal perforation or isolated limb gangrene but not both concurrently, suggesting a more virulent or late-stage disease in this patient.

The negative blood culture, despite clinical and serologic evidence, underscores the limitations of current diagnostic algorithms in typhoid-endemic, resource-poor settings, and calls for improved point-of-care testing and resistance surveillance.

This case highlights several key implications: The need for early suspicion of typhoid fever in febrile patients with abdominal symptoms, especially in endemic areas; The importance of early empirical antibiotics, surgical intervention, and critical care for complications like SPG and ECF; A call for improved sanitation, clean water access, and public health education to reduce typhoid burden; Consideration of vitamin C and antithrombotic therapy in cases of emerging SPG, especially where DIC is ruled out.

#### CONCLUSION

Typhoid fever continues to pose a significant public health challenge in sub-Saharan Africa. This case of colonic perforation with symmetrical peripheral gangrene illustrates the devastating complications of delayed diagnosis and underscores the need for early recognition, aggressive management, and health system strengthening to prevent such outcomes.

#### REFERENCES

1. Crump JA, Mintz ED. Global trends in typhoid and paratyphoid fever. *Clin Infect Dis*. 2010;50(2):241–246.
2. Bhan MK, Bahl R, Bhatnagar S. Typhoid and paratyphoid fever. *Lancet*. 2005;366(9487):749–762.
3. Anyanwu CH, et al. Symmetrical Peripheral Gangrene Associated with Enterocutaneous Fistula: A Case Report. *Niger J Surg*. 2016;22(2):129–133.
4. Bhutta ZA. Current concepts in the diagnosis and treatment of typhoid fever. *BMJ*. 2006;333(7558):78–82.
- WHO. Background document: The diagnosis, treatment and prevention of typhoid fever. Geneva: WHO; 2003.
5. Duguid JP. The 4 Fs: factors in the spread of enteric fever. *Lancet*. 1946;2:312–313.
6. Raffatellu M, et al. Host–pathogen interactions during Salmonella infections. *Immunol Rev*. 2008;225(1):154–167.
7. Kisku KH, et al. Peripheral Gangrene: A Rare Complication of Enteric Fever. *J Postgrad Med*. 2009;55(4):265–267.
8. Basnyat B, et al. Antibiotic treatment of typhoid fever in children: a systematic review. *BMJ*. 2005;330(7487):289–291.
- Parry CM, et al. Typhoid fever. *N Engl J Med*. 2002;347(22):1770–1782